

REFRACTIVE SURGERY

Lasik Surgical Technique: Tips and Pearls

Mark Cohen, MD, FRCSC

University of Sherbrooke

Sherbrooke, Quebec, Canada

Avi Wallerstein, MD, FRCSC

Director of Refractive Surgery

McGill University Health Center

Montreal, Canada

■ SURGICAL ATTIRE

Everyday street clothing was worn by some surgeons for PRK surgery prior to 1998. This practice has now been eliminated. Surgical scrubs are worn with sneakers or comfortable OR shoes. For laser in-situ keratomileusis (LASIK), interlamellar lint can arise from both street clothes and new surgical gowns. Therefore, new OR attire needs to be washed repeatedly before use. We wear a surgical cap to prevent particulate debris or loose hairs from falling near the operating field. Cosmetically, it also reassures patients of "sterility," although the technique is clean and not sterile. We do not use gloves for LASIK surgery but simply hand washing. Since discontinuing the use of surgical gloves in 1999, our medical group has not had a single incidence of corneal infection. Gloves can actually be a hindrance due to latex and talc. We wear a mask to decrease surgeon exposure to the corneal plume that rises during laser ablation.

■ SURGEON PREPARATION AND KERATOME CONFIRMATION

The surgeon must verify that the patient before them is the correct patient, even if all the staff has already done so. Say their name out loud and say their birth date. The more surgery you do, eventually you will find the wrong chart matched up to the wrong patient. Verify that the refraction entered into the laser is correct. Modify the refraction to your nomogram. Verify that the optical zone size chosen is adequate. Take one last look at the patient's pupils on the laser bed. Verify the residual stromal thickness calculation. Verify the keratome status and the correct choice of keratome head (relating to depth of cut), keratome ring size, and that all keratome compo-

nents are of the same serial number. Each Hansatome keratome (Bausch and Lomb) has a unique "fit" (still as of June 2003). Mismatched rings and heads can lead to high resistance and a keratome "jam" prior to completion of the flap, leading to incomplete and "short" flaps.

■ KERATOME HEAD AND RING CHOICES

One hundred sixty-micron heads are used for thin corneas and high scripts. One hundred eighty-micron flaps are used where "tissue is not an issue," and leaving behind a 250- μm stromal bed under the flap is easily achieved with enough tissue necessary for a retreatment. For head thickness, a regular 160 head flap measures 130-140 μm on average and a zero-compression 160 head ("Z16") measures 110-120 μm on average. A regular 180 head flap measures 140-150 μm on average, and the Z18 measures 130-140 μm . Standard deviations range from 14 to 25 μm . The size of the ring is chosen (8.5 mm or 9.5 mm) according to the corneal diameter, corneal blood vessel to vessel distance, and K readings. A micro suction ring (M-ring) is chosen for very narrow palpebral fissures, deep-set eyes, and prominent orbital

Choosing Ring Size

8.5 mm Ring:

Significant pannus, pterygium
Corneal vessel to vessel <9.5 mm
K > 46

M-Ring:

Narrow palpebral fissure
Deep set eyes
Prominent orbital rim

9.5 mm:

Flat K
Large diameter cornea
Most eyes

Address correspondence and reprint requests to Dr. Avi Wallerstein, 1250 Rene Levesque Blvd. West, Level RT, Montreal, Quebec Canada H3B 4W8; e-mail: awallerstein@lasikmd.ca

rims. An 8.5-mm flap is used for small corneas or steep corneas (>46 diopters [D]). A 9.5-mm ring is always used for flat corneas (<43 D) and normal-to-larger corneas. The 9.5 mm ring is used most of the time and whenever possible. Large flaps have the advantage of larger available treatment areas (particularly important with hyperopic treatments), greater flap stability postoperatively due to a broader hinge, extremely low risk of free cap (we have yet to see one with over 80,000 cases), and a greater zone of “safety,” should epithelial ingrowth occur.

■ PREOPERATIVE MEDICATIONS AND ANESTHESIA

Some surgeons routinely use topical antibiotics before surgery. We feel it is not necessary and do not. We also do not prep the eyelids with povidone iodine (Betadine, Perdue Farmer). Our group of surgeons has not had a single case of flap infection in over 80,000 procedures. We use preoperative lid scrubs in cases where there is persistent eye makeup or significant blepharitis. We do not use scrubs routinely for normal eyes. Sublingual lorazepam (Ativan, Wyeth-Ayerst) is offered 20 minutes before surgery to those patients who want a relaxant. Over 90% of patients take no sedative before the surgery. Alcaine is used as anesthetic drops and is instilled immediately before surgery, eliminating epithelial toxicity. Several topical anesthetic drops are placed into the eye and the lids are wiped dry. If the lids are not dry, tape to the lashes will not stick. A conjunctival pledget is not necessary, but can be helpful to those patients with very sensitive eyes, and for reassurance that nothing hurts when the surgeon touches.

■ THE SURGICAL FIELD AND LID SPECULUM

We do not drape the surgical field. Transpore tape is used to tape the lashes out of the way and to cover the lower lid to prevent “nicking” of the lower lid by the keratome blade during its forward pass. Two pieces of tape are used for the upper lid (nasal and temporal) and one for the lower lid. The other eye is taped shut. The Lieberman adjustable lid speculum is placed under the upper lid first with the patient looking at the fixation light. We avoid touching the epithelium. The patient is advised not to squeeze the eyes to avoid a Bell’s reflex, which could cause an abrasion. The speculum is then placed under the lower lid. The eyelids are held with the nasal hand while the temporal hand of the surgeon holds the lid speculum. The speculum is opened gently and slowly to prevent reflex squeezing. Once open, ensure that there are no lashes or tape in the way of the keratome pass.

■ KERATOME RING PLACEMENT

We use a 4-mm ring to mark the cornea with blue ink at the 4-o’clock and 8-o’clock positions prior to ring placement. Although corneal markings are not needed 99% of the time for an advanced surgeon, they are useful in those very rare cases of narrow hinges where the flap is difficult to reposition in its exact place, or in the case of a free flap.

Prior to placement of the ring, the eye must be in proper position. That position is obtained by moving the head. The first head position is for the keratome pass. Raise the chin up or down to center the eye within the palpebral fissures. Then tilt the head nasally to place the eye in a slightly temporal position, allowing greater exposure. Obtaining the appropriate position is crucial prior to starting, and a great deal of time is taken to ensure it. We are always looking for something that could interfere with the keratome pass.

The ring is generally placed in the center of the cornea. Centration is determined in relation to the limbus and the pupil. Situations where the ring is decentered slightly would include (for advanced surgeons only)

1. a significant angle kappa (may be noted on topography or at the laser). For these patients, particularly with hyperopia, the ring may be decentered slightly superiorly between the center of the cornea and the visual axis.
2. corneal neovascularization (pterygium, pannus). The ring can be decentered away from the blood vessels to avoid intraoperative bleeding
3. hyperopia. The keratome ring may be decentered superiorly to increase the area of treatment.

What appears in the microscope to be a 1-mm decenteration becomes 2 mm. So use caution. Centration of the ring is very important. Take your time and check again. After centration of the ring, firm pressure is applied to the limbus with the ring for several seconds. We call this technique scleral “grooving.” This allows an indentation to be created that will prevent the ring from sliding once suction is applied. This is particularly important in large and flat corneas where “cornea sliding syndrome” often occurs. It is typically a temporal sliding of the ring upon the application of suction. If significant sliding does occur, the keratome pass is not started, and suction needs to be stopped and the ring recentered. A longer period of pressure prior to suction (15–30 seconds) will be necessary to prevent “sliding,” and sometimes decentering in the opposite direction anticipating the sliding can help.

While applying pressure with the corneal ring, the speculum is depressed with the hand opposite that hold-

ing the ring handle. The nasal handle is held with the left hand for the right eye and the right hand with the left eye. Speculum depression allows for globe proptosis to improve cornea/scleral contact with the footplate of the ring. It also tightens the conjunctiva, avoiding loose and boggy conjunctiva from being sucked into the port, creating pseudosuction.

■ VACUUM AND SUCTION

Calibration of the Hansatome Vacuum pump is performed twice a day to ensure that the pressure level is set at 3.5 mm below atmospheric pressure. Vacuum is commenced with the single foot switch, usually performed by the assisting technician. An audible beeping occurs as suction pressure increases. When the beeping stops, appropriate suction is obtained. Adequate suction is assured by several means: audibly, when the “beeps” from the pump stop; visibly, by seeing a dilation of the pupil; physiologically, by asking the patient if the vision is “going dark.” With adequate suction, intraocular pressure exceeds the ocular perfusion pressure, resulting in a temporary reduction in retinal blood flow. This leads to the perception of vision “going dark, gray, or blank.” The last method is by applanation tonometry with a Barraquer tonometer. We have stopped this step because the first three are quite reliable in experienced hands. The tonometer step adds time, occasionally introduces foreign material to the cornea surface, and is questionably accurate.

Obtaining Adequate Suction

1. Audible beeping ends
2. Wait 3 to 5 seconds
3. Vacuum pressure 3.5 mm Hg below atmospheric
4. Vision goes dark or blank
5. Pupil dilation
6. Barraquer tonometer reading

■ FLAP CREATION

Before engaging the keratome into the ring on the eye, the “forward” pedal of the foot switch is depressed and the keratome is placed next to the patient’s ear. We call this the “buzzing” test. It allows the patient to hear the normal sound of the oscillating blade, so that they are not surprised and do not “jump” when the keratome is placed on the eye. It also allows the surgeon to hear the sound of the blade, which gives him an audible indication of blade resistance and ensures normal blade movement. An improperly inserted blade will not oscillate normally.

The surgeon can also look at the blade moving. The surgeon should also confirm that the resistance readings on the vacuum pump are within range, usually below 20 when testing and below 50 when on the eye. Once appropriate suction is obtained, the cornea is generously lubricated with proparacaine drops. Some surgeons choose to apply viscous teardrops prior to the pass, we do not. Since the use of the Zero Compression Hansatome, the incidence of corneal abrasions has fallen to about 0.1%, minimizing the need for thicker lubrication. The keratome is then placed on the pivot post. It should fall easily into place, if it is maintained vertical and the ring horizontal. The keratome is pushed down slightly to indent the cornea and rotated forward so that the gears touch the ring’s teeth. The patient is warned not to move or jump. We make sure there is no tension or pulling on the motor cord or suction tubing to avoid torque to the ring. Prior to proceeding with the cut, the eye is gently superiorly rotated and elevated to avoid nicking the lower lid. The forward foot pedal is now depressed. The keratome proceeds forward until it reaches the stopper when 2 beeps are heard and then it is reversed. The pass is observed both inside and outside the scope. The surgeon should then clearly ask the technician for “suction off.” After a momentary wait, to allow the suction to decline, the ring and keratome head are lifted off together. The speculum is now loosened to make the patient more comfortable. The patient’s head is now repositioned to its natural placement. This is head position number 2, in preparation for laser ablation. The eye position is verified to be in the horizontal plane perpendicular to the laser pulses. The patient is reminded to look in the center of the fixation light or the “big red starburst of light.”

■ RAISING THE FLAP

Using a precut Weck cell sponge generously swollen with balanced salt solution, a “pillow” is created upon which the flap rests at the 12-o’clock position. It prevents the flap from touching the conjunctiva. In some cases, the flap edge is dried prior to lifting to avoid dragging fluid onto the stromal bed. A fine nontoothed angled forceps is used to raise the flap. The flap is never grabbed or pinched. The flap is raised by insertion of the forceps at the edge of the flap at the level of the inferior part of the pupil (below the visual axis), one third of the way toward the hinge. The flap is then very slowly and gently lifted. The action is analogous to opening a door or a hatch. This step should never be rushed, and the flap should never be pulled. Pulling a flap and allowing it to stick to the underlying stromal bed will create stretching of the very thin tissue (often less than 100 μm) with permanent anatomic changes. These stretching changes

manifest as white/gray lines that are breaks in Bowman's layer. If severe, they can be visually significant. It is also important to maintain the flap's concavity as it rests on the pillow to prevent these "lacquer cracks."

■ LASER TREATMENT

The stromal bed is dried by tamponade, only if necessary, with a dry Weck sponge, being careful not to wipe, which leaves more particulate matter. The laser is focused again and the tracker is reverified. Horizontal eye positioning is important and verification looking outside the scope from the temporal side of the patient can be done. The patient is constantly reminded to look up at the center of the fixation light. The laser treatment entered into the laser is looked at one last time. The laser foot pedal is pressed. Dim tangential lighting during laser ablation is used, to allow pupil visualization and fluorescence of the actual treatment and any debris on the stromal bed. For hyperopic treatments and treatments where laser pulses encroach on the undersurface of the flap, a flap protector (semiwet Weck sponge) is used to block laser pulses from hitting the flap.

■ FLAP REPOSITIONING

The flap is replaced by applying the forceps or the cannula to the epithelial side of the superior part of the flap, near the hinge. One or two drops of balanced salt solution at the hinge may be used, creating a fine evened-out aqueous layer upon which the flap rests or floats. The

flap is replaced to align with its gutters and with the 4-o'clock and 8-o'clock corneal markings. *Minimal* irrigation is used to ensure that the flap is replaced properly. It is important not to irrigate generously. There is no evidence that lots of irrigation prevents DLK, or lessens debris. Irrigation has many drawbacks. It creates flap swelling, which causes the flap to retract at the gutters. Swelling and retraction lead to more difficult and less accurate flap replacement. The large gutter space, flap swelling, and inaccurate positioning can lead to poor adherence, resulting in striae and epithelial ingrowth. Vision is also significantly worse immediately post-operatively with a swollen flap than with a "dry technique." The small amount of fluid under the flap is squeezed out by barely touching with a cannula or a very wet spear. The flap is gently extended and distended in place. As opposed to the early days of LASIK, when several minutes of "adherence time" were given for the flap to dry and begin adhering, currently we wait no more than a few seconds following flap replacement prior to removing the speculum. Waiting has no added benefit with a "dry technique." The speculum is removed lower lid first, carefully and by pulling away from the eye, to avoid touching the flap. The patient is asked to continue looking straight at the fixation light. The tape is then removed, also by pulling the lids away from the eye to avoid the tape from touching the cornea. After completion of both eyes, the flaps are immediately verified at the slit lamp, then again after 45 minutes, to ensure correct placement with no striae or significant debris.

■ PRODUCT REVIEW ■

Bausch and Lomb Hansatome Microkeratome

Avi Wallerstein, MD, FRCSC

*Director of Refractive Surgery
McGill University Health Center
Montreal, Canada*

The Bausch and Lomb Hansatome corneal microkeratome is the world's most commonly used keratome for refractive surgery. It was conceived and developed by Hans Hellenkamp, the developer and manufacturer of the Automated Corneal Shaper (ACS). The ACS was originally developed for automated lamellar keratomileusis (ALK), and its combination with the excimer laser led to the advent of the LASIK (laser in-situ keratomileusis) procedure.

The Hansatome was specifically configured for the LASIK procedure and was designed to eliminate many

of the complications and problems that previously existed with the ACS keratome. It was originally released in 1997 and included a 160- μ m head, a 180- μ m head, and a 9.5-mm ring for 9.5-mm-diameter flaps. The Hansatome was the first keratome to incorporate a superior hinge. The superior hinge has certain advantages. It is more physiologic and works with lid motion and gravity, the hinge is further away from the visual axis with less potential to induce cylinder, it provides a larger overall treatment zone for scanning astigmatic ablations and hyperopia, and it is less likely to get displaced.

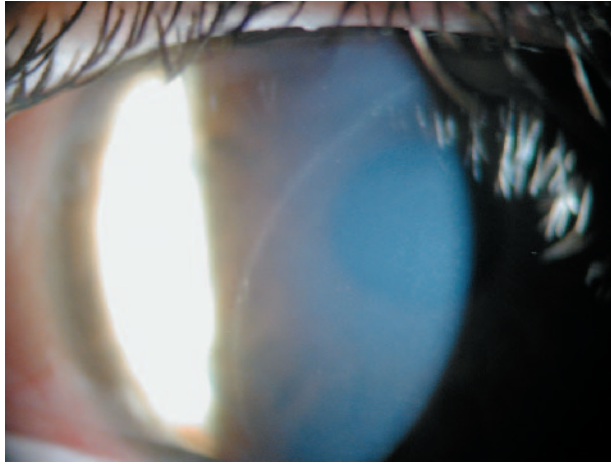


FIGURE 1. Short flap with faint scar at pupil margin.




FIGURE 2. Keratome suction ring sizes, 8.5 mm and 9.5 mm.

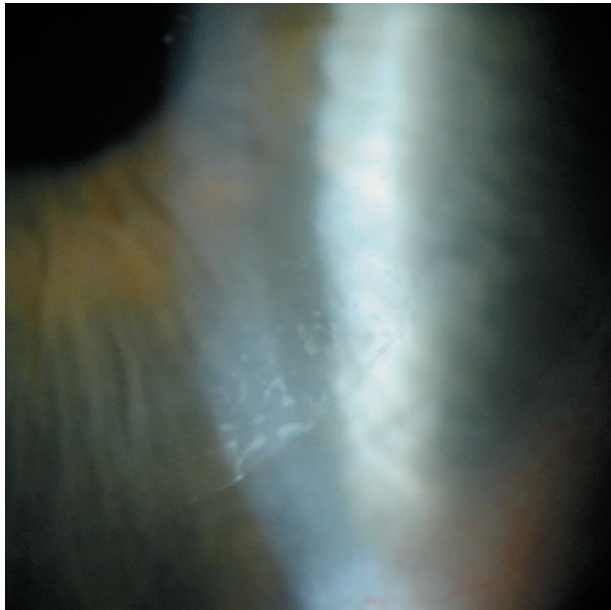


FIGURE 3. Sheet of epithelial cells with cysts invading below the flap edge.

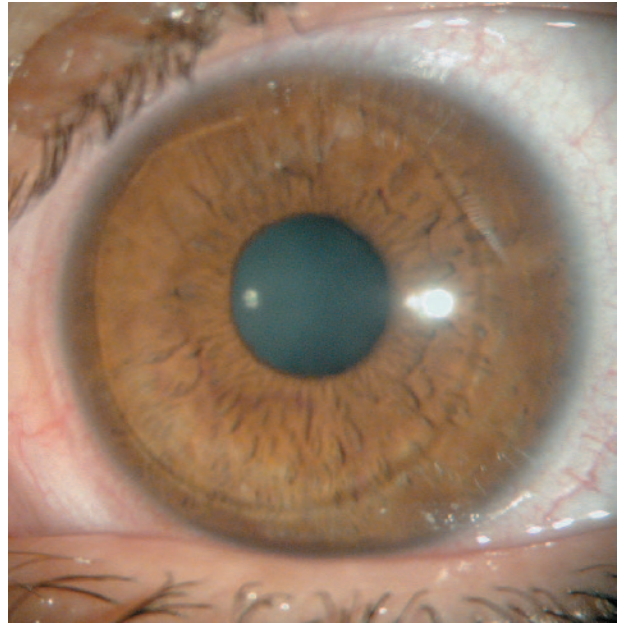

FIGURE 4. Moderately decentered flap.



FIGURE 5. Hansatome Vacuum Pump Box.

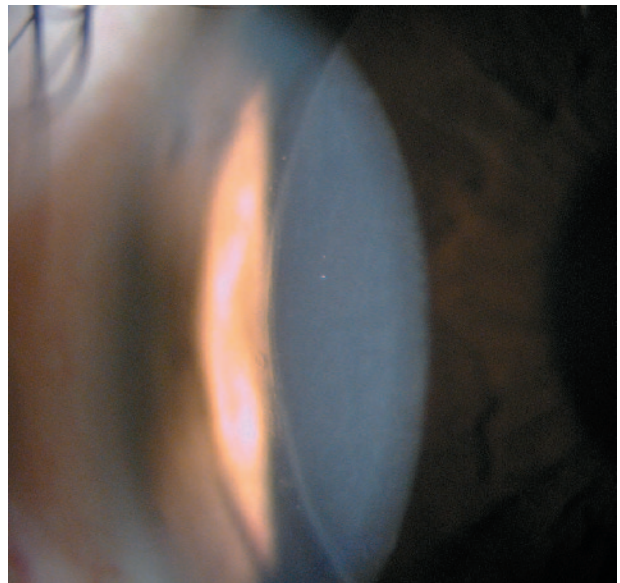


FIGURE 6. Well-opposed flap edge immediately after surgery.

The Hansatome's original design incorporated several benefits and safety features. These include

1. a 3-step assembly for easy preparation; far fewer than the ACS
2. a fixed-depth plate, which eliminates the risk of perforation. Perforation is the most severe intraocular complication that can occur with LASIK. It is essentially impossible with the Hansatome with a cornea of normal thickness.
3. an ergonomic pivot post that makes loading simple.
4. a single rolling gear that creates smooth translation.
5. 9.5-mm flap resection to allow larger treatment zones.
6. a plastic blade holder for convenient insertion and faster oscillation.
7. a nasally located elevated rack to prevent impeded forward progress.

The power supply of the Hansatome also added the following safety features and benefits:

1. Internal diagnostic tests ensure system integrity prior to each procedure
2. Audible and visual indication of suction status and microkeratome performance.



FIGURE 7. Hansatome Microkeratome.



FIGURE 8. Keratome assembly.

3. Cutting motion that cannot start or progress unless appropriate vacuum level is achieved and maintained.
4. A backup power system will allow completion of a case in the event of power failure.
5. Electronic compensation that delivers constant motor speed.
6. A dynamic braking system that electronically detects stop to minimize stress on motor and gears.

Subsequent upgrades to the Hansatome include the release of an 8.5-mm ring for smaller diameter flaps for smaller corneas (1998). The “zero compression” version (2001) was specifically engineered to eliminate intraoperative corneal epithelial abrasions. The incidence of epithelial abrasions has been almost completely eliminated, even in patients with mild to moderate Map Dot Fingerprint dystrophy. The 200- μm head, for thicker flaps, and the “microsuction ring” (2001) were also added. The M-ring is specifically designed for patients with small interpalpebral fissures, deep-set orbits, and smaller protruding orbital rims. The Hansatome pump LED backlighting (2002) was added to improve visibility of the LED information displayed on the pump.

The Hansatome is user friendly and a delight to operate. The learning curve is small for the beginning surgeon, while the advanced surgeon can complete surgery on just about any eye. That includes small orbits and palpebral fissures as well as flat and steep corneas (38–50 D). With proper cleaning and care, the unit can be used for thousands of cases without service. It is most reliable and safe. If properly maintained, flap complications almost never occur due to instrument failure.