

# Corneal Biopsy

Pierre E. Demers, MD, FRCSC

Assistant Professor of Ophthalmology, Notre-Dame Hospital, University of Montreal Hospital Centers, Quebec, Canada

## ABSTRACT

Although rarely performed, corneal biopsy may be useful in establishing the diagnosis and prompt institution of appropriate management in progressive keratitis of unknown cause. Inability to obtain a definitive diagnosis in a case of chronic keratitis may be related to previous use of antimicrobials that interfere with standard cultures or by the fastidious growth of unusual pathogens in culture. Surgical techniques employed for corneal biopsy, as well as proper processing of corneal specimens for microbiologic or histopathologic studies, will be reviewed. Indications and concerns about the procedure will also be addressed.

## HISTORICAL PERSPECTIVE

Reports on corneal biopsy started to appear more frequently in the ophthalmic literature during the 1980s. The technique became an exciting adjunct to the clinician's diagnostic armamentarium as atypical forms of infectious keratitis unresponsive to available antimicrobial therapy were appearing more frequently. This may be explained by the increased popularity of soft contact lenses in the early 1980s. Better comfort and more affordable lenses brought freedom from glasses to millions of people, coinciding with an increased incidence of chronic keratitis caused by parasitic infections.<sup>1</sup> Although corneal scrapings may sometimes reveal acanthamoebal cysts, especially early in the disease process when the pathogen is located more superficially, corneal biopsy has proved to be more dependable in providing a more definitive diagnosis in chronic cases of parasitic keratitis.<sup>2-6</sup>

In fungal keratitis, examination of specimens obtained by corneal biopsy were also found to be superior in quality and yield than corneal scrapings.<sup>7-9</sup> In addition, scrapings failed to find a causative pathogen in 19% to 27% of cases of bacterial keratitis.<sup>10,11</sup>

Address correspondence and reprint requests to Dr. Pierre E. Demers, Assistant Professor of Ophthalmology, Notre-Dame Hospital, University of Montreal Hospital Centers, 1560 Sherbrooke St. East, Montreal, Quebec Canada H2L 4M1; e-mail: pdemersey@aol.com

However, the need for corneal biopsies has waned in the last decade. Newer and more potent antibiotics for bacterial keratitis, as well as keen awareness of unusual microorganisms and institution of immediate and appropriate cultures and therapy in cases of fungal, parasitic, and mycobacterial infections, has made the need for corneal biopsy less necessary.

## TECHNIQUE

No preoperative medication is usually necessary, although oral anxiolytics may help in younger and nervous patients. Biopsy may be done in a major or minor surgical setting under scope magnification.

In phakic patients, pilocarpine 2% should be given to protect the lens in the event of an inadvertent perforation and also to reduce photophobia from the surgical light.

Retrobulbar or peribulbar anesthesia is usually unnecessary except in patients who are not cooperative to undergo the procedure, in intensely inflamed and painful eyes, and in whom akinesia is primordial (full-thickness biopsy). Topical proparacaine 0.5% or a subconjunctival injection of lidocaine 2% with epinephrine is usually sufficient for most cases of partial-thickness biopsy. A sponge soaked in proparacaine and placed on the limbus for 1-2 minutes can help with anesthesia when forceps are needed to fixate the globe.

The microbiologist and pathologist should be contacted prior to biopsy to secure appropriate culture media and stains (Table 1) for the former and appropriate storage media (Table 2) and stains (Table 3) for the latter.

Several techniques have been proposed in the literature<sup>12,13</sup>; they include variations of partial- and full-thickness biopsy techniques. Regardless of technique, one should always avoid the central visual axis when

**TABLE 1.** Microbiologic evaluation of corneal biopsy or biopsy site scraping of unusual and fastidious organisms

| Transport Media                               | Screening            |
|---|----------------------|
| Sabouraud agar                                | Fungi                |
| Nonnutrient agar with <i>Escherichia coli</i> | <i>Acanthamoeba</i>  |
| Lowenstein-Jensen agar                        | <i>Mycobacterium</i> |
| Thioglycolate broth                           | Anaerobes            |
| Viral transport medium                        | Herpesvirus          |

**TABLE 2.** Transport media for histopathologic evaluation of corneal biopsy

| Transport Media  | Screening                             |
|------------------|---------------------------------------|
| 10% Formaldehyde | Routine histopathology                |
| Sterile saline   | <i>Acanthamoeba</i> , fungi, bacteria |
| Glutaraldehyde   | Electron microscopy                   |

possible, and always include both uninvolved and diseased tissue in the sample. Additionally, the leading mar-

*When performing the biopsy, avoid the central visual axis when possible.*

gin of a progressive infiltrate usually gives a higher diagnostic yield while preventing inadvertent perforation

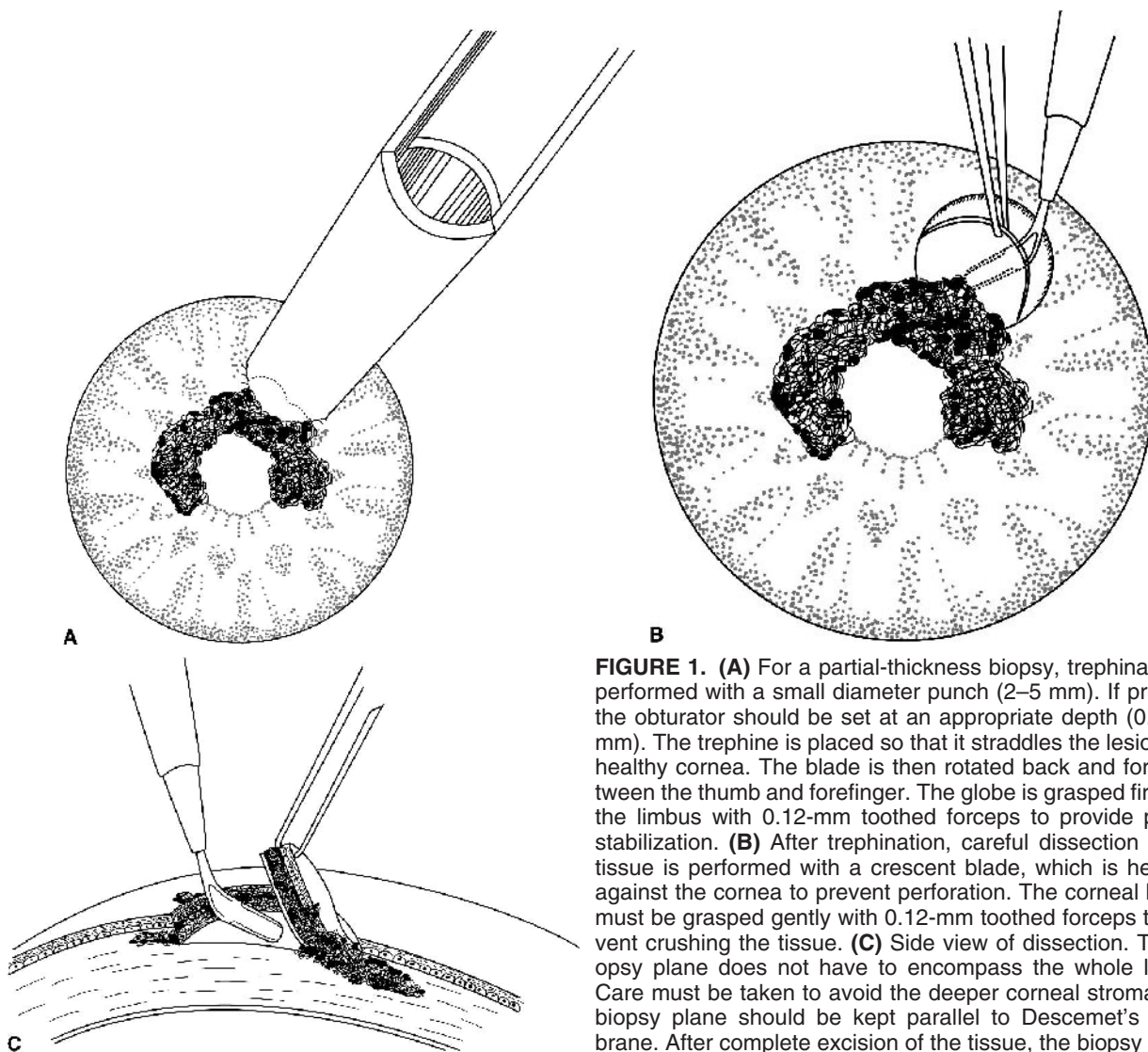
**TABLE 3.** Stains for histopathologic evaluation of corneal biopsy

| Stains                                 | Screening                   |
|--|-----------------------------|
| Gomori's methenamine silver or Grocott | Fungi                       |
| Periodic acid-Schiff, calcofluor white | <i>Acanthamoeba</i> , fungi |
| Brown-Brenn, Brown-Hopps               | Bacteria                    |
| Ziehl-Nielsen acid fast                | <i>Mycobacterium</i>        |

in the center of the lesion, which is usually composed of edematous or thinned necrotic tissue.

A partial-thickness biopsy should be performed first. We reserve full-thickness biopsy for tectonic reasons in advanced disease.

Most often used methods of biopsy currently used are



**FIGURE 1.** (A) For a partial-thickness biopsy, trephination is performed with a small diameter punch (2–5 mm). If present, the obturator should be set at an appropriate depth (0.2–0.3 mm). The trephine is placed so that it straddles the lesion and healthy cornea. The blade is then rotated back and forth between the thumb and forefinger. The globe is grasped firmly at the limbus with 0.12-mm toothed forceps to provide proper stabilization. (B) After trephination, careful dissection of the tissue is performed with a crescent blade, which is held flat against the cornea to prevent perforation. The corneal button must be grasped gently with 0.12-mm toothed forceps to prevent crushing the tissue. (C) Side view of dissection. The biopsy plane does not have to encompass the whole lesion. Care must be taken to avoid the deeper corneal stroma. The biopsy plane should be kept parallel to Descemet's membrane. After complete excision of the tissue, the biopsy specimen is transferred from the crescent blade to the appropriate transport media.

*Always include both healthy and diseased tissue in the sample.*

1) trephination (Figs. 1A–C) and 2) free lamellar dissection (Fig. 2). Trephination may be accomplished with a number of systems. At our center, we prefer using the Elliot Punch, which has a 2-mm opening, making it easier and safer to use in smaller or more centrally located lesions. It is a manual trephine, so care must be exercised not to cut too deeply into the lesion. Trephines that have adjustable obturators should be preset at a depth of 0.2 to 0.3 mm. These trephines can be found in sizes ranging from 3 to 5 mm. For lamellar biopsies, a stainless steel blade or a radial keratotomy diamond knife can be used.

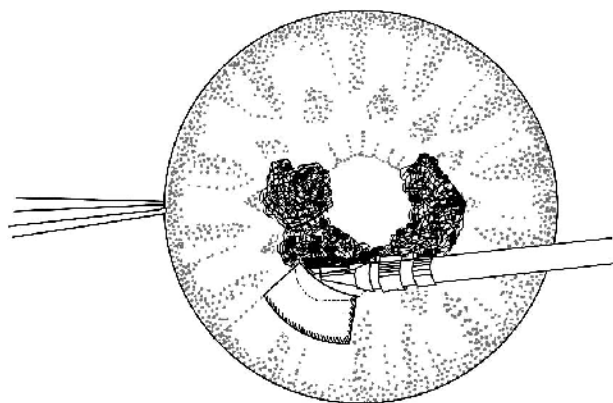
After the biopsy is done, the stromal bed under the biopsy site should be scraped with a Bard-Parker #15 blade and appropriate cultures streaked.

Postoperatively, in the case of suspected microbial keratitis, the same antimicrobial regimen is continued. An antibiotic ointment may be added for comfort during the day and at nighttime. We do not patch the eye routinely, unless a full-thickness biopsy is performed.

## ■ DISCUSSION

Corneal biopsy should be performed for a culture-negative keratitis that does not respond to empirical topical broad-spectrum antibiotics, or for deeper infiltrates that cannot be accessed for surface scraping.

A corneal biopsy should be performed immediately when patients are referred to a tertiary care center after



**FIGURE 2.** Alternatively, a partial-thickness biopsy may be achieved with lamellar keratectomy. The biopsy site may be outlined with the tip of an RK diamond knife or with the edge of a Beaver 57 blade stained with a Gentian Violet pen or pad. The RK diamond knife is preset at the desired depth (0.2–0.3 mm). The incision should be angled to ensure a smooth transition between the biopsy site and neighboring cornea to avoid creating a divot, therefore minimizing the probability of inducing irregular astigmatism.

months of unresponsiveness to seemingly appropriate antimicrobial therapy. We usually do not stop the topical therapy 24–48 hours before obtaining tissue specimens.

If a patient has just started antimicrobial therapy for a severe corneal infiltrative ulcer and no clinical improvement is seen after 48–72 hours, we proceed to a second scraping for cultures that may be positive even after a primary negative result. If the second culture is

*It is best to hand-deliver the biopsy specimen to the pathologist or microbiologist.*

negative, and if classic clinical signs of fungal (satellite lesions, feathery edges) or parasitic infiltration (perineural involvement) are absent, we then proceed to corneal biopsy.

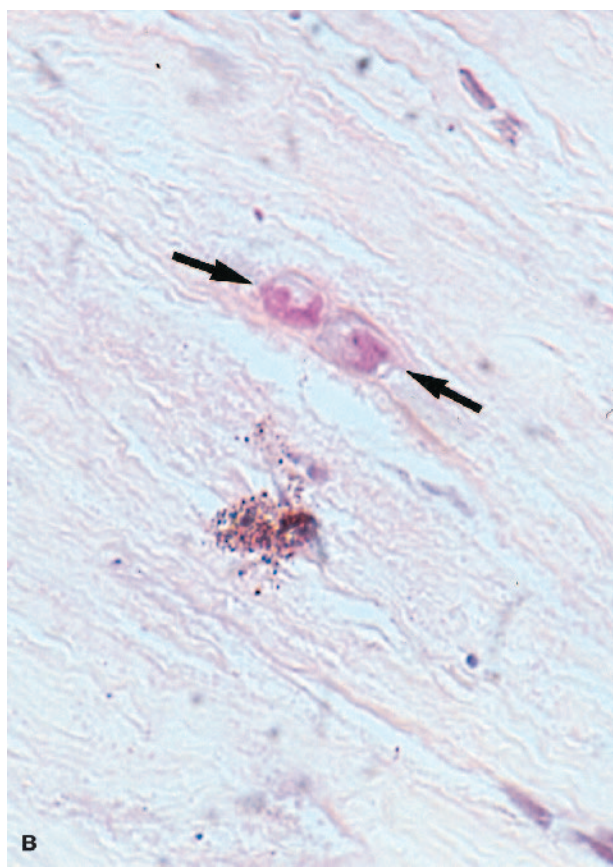
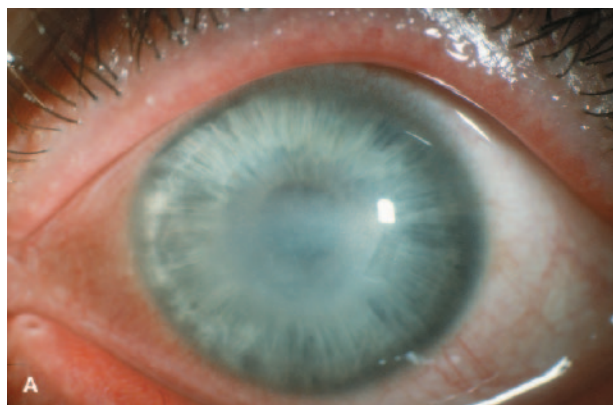
The size of the biopsy specimen should be sufficient to permit adequate study with appropriate cultures and stain. A 3–5-mm specimen may be bisected and sent to microbiology and pathology laboratories. A specimen less than 3 mm should be processed by only one technique. Some advocate sending a unique specimen for microbiologic evaluation, while others prefer histopathologic screening. One may choose either screening method, depending on the experience of diagnostic laboratories in handling small tissue specimens and in recognizing atypical and rare occurrence of corneal disease.

*Many histopathologic studies can be done within 24 hours of biopsy, permitting more rapid identification of fastidious microorganisms when compared with microbiologic testing.*

Urgency for clinical diagnosis may also dictate which laboratory gets the tissue. While growing and identifying fastidious organisms in special culture media may take several days or weeks, examination of embedded acanthamoebal cysts (Figs. 3A, B) or hyphal elements (Figs. 4A, B) on a histopathologic slide may take as little as 4 hours and at most 1–2 days.

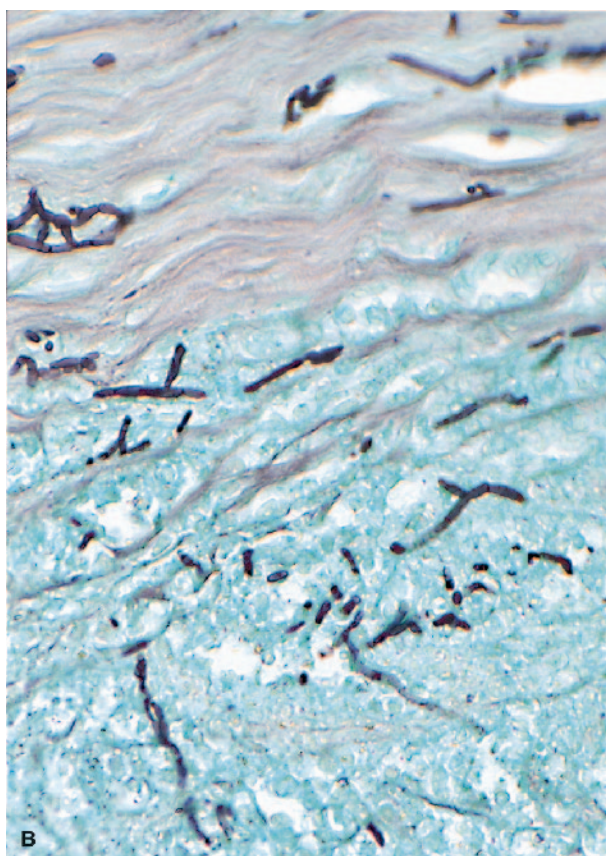
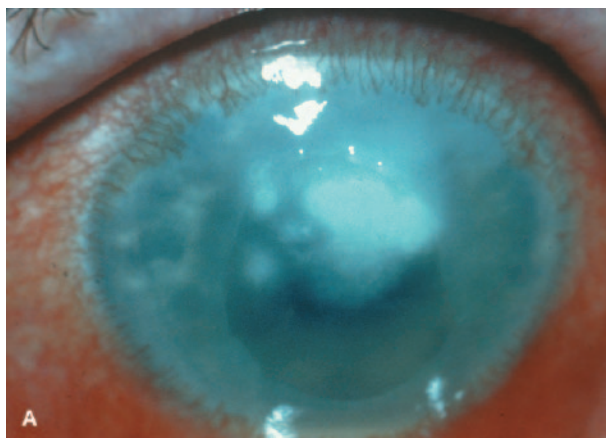
Complications from biopsy include scarring, irregular astigmatism, poor or delayed healing, and perforation. Careful technique, lubrication, and management of ocular surface disease will prevent complications.

Corneal biopsy is a safe but invasive technique. It is hoped that newer and more sensitive staining techniques for corneal surface scrapings may decrease the need for corneal biopsy. Recently, special stains such as calcofluor white for fungi<sup>12</sup> and *Acanthamoeba*<sup>13</sup> organisms have shown promise in increasing the yield of positive findings from scrapings. Polymerase chain reaction as-



**FIGURE 3. (A)** Right eye. Paracentral, irregular stromal corneal ring infiltrate. A 32-year-old man presented with chronic keratitis lasting 2 months and unresponsive to topical antibiotics, antivirals, and corticosteroids. History was positive for swimming in a public pool with his contact lenses on. Corneal biopsy was immediately performed to rule out *Acanthamoeba*. A lamellar biopsy was performed with an RK knife set at 0.25 mm (arrow). **(B)** Two *Acanthamoeba* cysts (arrow) in corneal stroma from biopsy of 32-year-old man: Hematoxylin–phloxin–safran stain (×400).

says have also allowed the rapid screening of DNA extracted from specimens extracted from corneal buttons for potential fungal contamination<sup>14</sup> and herpetic keratitis<sup>15</sup> or from surface scrapings from patients with sus-



**FIGURE 4. (A)** Right eye. Superior corneal stromal infiltrate with satellite abscesses in 34-year-old man 3 weeks after being struck by vegetable matter. Lesion worsened despite topical antibiotics and corticosteroids. Corneal biopsy was performed to rule out fungus. **(B)** Numerous septate hyphae showing 45° branching in the corneal stroma from biopsy of 34-year-old man. Cultures were positive for *Aspergillus* sp. Grocott stain (×400).

pected *Acanthamoeba*,<sup>16</sup> mycobacterial,<sup>17</sup> and bacterial keratitis.<sup>18</sup>

A promising new approach in the diagnosis of chronic keratitis is the use of confocal microscopy. This device allows in vivo examination of the cornea with

sufficient magnification to identify acanthamoebal cysts,<sup>19</sup> fungal hyphae,<sup>20</sup> and bacterial hyperreflective bodies.<sup>21</sup> Improved imaging may bring more widespread use of this new technology, which may lessen the need for corneal biopsy in the future. However, when the diagnosis of chronic keratitis is uncertain, corneal biopsy should be considered as a safe and very effective means of obtaining a definitive diagnosis.

## ■ ACKNOWLEDGEMENTS

Dr. Guy Allaire, ophthalmic pathologist at the University of Montreal University Centers, is acknowledged for his participation in the manuscript and for his histopathologic photographs.

## ■ REFERENCES

- Moore MB, McCulley JP, Luckenbach M, et al. Acanthamoeba keratitis associated with soft contact lenses. *Am J Ophthalmol* 1985;100:396-403.
- Alexandrakis G, Haimovici R, Miller D, et al. Corneal biopsy in the management of progressive microbial keratitis. *Am J Ophthalmol* 2000;129:571-576.
- Newton C, Moore MB, Kaufman HE. Corneal biopsy in chronic keratitis. *Arch Ophthalmol* 1987;105:577-578.
- Friedlander MH. Corneal biopsy. *Int Ophthalmol Clin* 1988;28:101-102.
- Lee P, Green WR. Corneal biopsy. Indications, techniques, and a report of a series of 87 cases. *Ophthalmology* 1990;97:718-721.
- Diamant JI, Abbott RL. Surgical management of infectious and noninfectious keratitis. *Int Ophthalmol Clin* 1998;38:197-217.
- Ishibashi Y, Kaufman HE. Corneal biopsy in the diagnosis of keratomycosis. *Am J Ophthalmol* 1986;101:288-293.
- Ishibashi Y, Hommura S, Matsumoto Y. Direct examination vs culture of biopsy specimens for the diagnosis of keratomycosis. *Am J Ophthalmol* 1987;103:636-640.
- Legeais JM, Blanc V, Basset D, et al. Kératomycoses sévères. Diagnostic et traitement. *J Fr Ophthalmol* 1994;17:568-573.
- Jones BR. Initial therapy of suspected microbial ulcers: II. Specific antibiotic therapy based on corneal smears. *Surv Ophthalmol* 1979;24:105-116.
- Asbell P, Stenson S. Ulcerative keratitis: survey of 30 years' laboratory experience. *Arch Ophthalmol* 1982;100:77-80.
- Arffa RC, Avni I, Ishibashi Y, et al. Calcofluor and ink-potassium hydroxide preparations for identifying fungi. *Am J Ophthalmol* 1985;100:719-723.
- Silvany RE, Luckenbach MW, Moore MB. The rapid detection of Acanthamoeba in paraffin-embedded sections of corneal tissue with calcofluor white. *Arch Ophthalmol* 1987;105:1366-1367.
- Kercher L, Wardwell SA, Wilhelmus KR, et al. Molecular screening of donor corneas for fungi before excision. *Invest Ophthalmol Vis Sci* 2001;42:2578-2583.
- Rong BL, Pavan-Langston D, Weng QP, et al. Detection of herpes simplex virus thymidine kinase and latency-associated transcript gene sequences in herpetic corneas by polymerase chain reaction amplification. *Invest Ophthalmol Vis Sci* 1991;32:1808-1815.
- Mathers WD, Nelson SE, Lane JL, et al. *Arch Ophthalmol* 2000;118:178-183.
- Frueh BE, Dubuis O, Imesch P, et al. Mycobacterium szulgai keratitis. *Arch Ophthalmol* 2000;118:1123-1124.
- Pinna A, Sechi LA, Zanetti S, et al. Bacillus cereus keratitis associated with contact lens wear. *Ophthalmology* 2001;108:1830-1834.
- Winchester K, Mathers WD, Sutphin JE, et al. Diagnosis of Acanthamoeba keratitis in vivo with confocal microscopy. *Cornea* 1995;14:10-17.
- Winchester K, Mathers WD, Sutphin JE. Diagnosis of Aspergillus keratitis in vivo with confocal microscopy. *Cornea* 1997;16:27-31.
- Kaufman SC, Laird JA, Cooper R, et al. Diagnosis of bacterial contact lens related keratitis with the white-light confocal microscope. *CLAO J* 1996;22:274-277.

## ■ CLINICIAN'S CORNER ■

Paul Thompson MD, FRCS(C)

Associate Professor, Department of Ophthalmology,  
University of Montreal, Montreal, Canada

Michèle Mabon, MD, FRCS(C)

Assistant Professor, Department of Ophthalmology,  
University of Montreal, Montreal, Canada

What is the main problem you encounter when performing corneal biopsies?

*Dr. Thompson:* The depth of incision is difficult to evaluate when performing a corneal biopsy. To enhance safety and guard against perforation when performing a

deep biopsy in severely diseased tissue, a guarded trephine should be used. Conversely, a slit-lamp could be attached to the operating microscope to better visualize the incision site. Another approach is to obtain a half-depth biopsy using a blade or a small trephine. If the

biopsy is negative, a deeper lamellar dissection can be performed at the previous biopsy site using a metal or diamond blade.

*Dr. Mabon:* Undoubtedly, the greatest problem encountered is to acquire adequate tissue without inflicting structural damage or irreversible optical damage. Adding further to this already difficult challenge is that the tissue is often necrotic, which inadvertently increases the size of the biopsy area.

■ **HOW WOULD YOU ENHANCE THE YIELD IN HISTOPATHOLOGY RESULTS WHEN PERFORMING CORNEAL BIOPSY?**

*Dr. Thompson:* Ideally, all antimicrobial agents should be discontinued 24 to 48 hours before obtaining biopsy. Since fungi may be present only in the deep stroma and at the margin of the infiltration, the biopsy specimen must include deep lamellar tissue and incorporate both clinically infected and adjacent clear cornea. A good communication with the microbiologist or the pathologist is mandatory.

*Dr. Mabon:* Allowing both the microbiology and pathology personnel to handle and process the small biopsy sample would increase yield. The biopsy sample should also include the leading edge of the ulcer, where often, more organisms can be found. Also, an often forgotten pearl is to first pass a 10-0 nylon suture into the ulcer site in an attempt to gather organisms along the suture. The suture segment used can then be dragged on appropriate culture media in the operating room.

■ **WHAT IS THE MAIN ORGANISM ISOLATED IN YOUR EXPERIENCE?**

*Dr. Thompson:* In cases of posttraumatic keratitis, the main pathogens isolated from corneal biopsies in our

microbiology laboratory were filamentous fungi belonging to *Aspergillus*, *Fusarium*, or *Alternaria* species. *Candida* was isolated mainly from patients taking immunosuppressive drugs or having preexisting corneal diseases. *Acanthamoeba* cysts were frequently detected in biopsy specimens from contact lens users presenting a ring-shaped stromal infiltrate.

*Dr. Mabon:* Atypical bacteria, including *Nocardia* and MOTT (mycobacteria other than tuberculosis) including *Mycobacterium chelonae*–*fortuitum* complex are sometimes isolated. Fastidious organisms such as *Streptococcus viridans* and *Acanthamoeba* as well as fungi are hopefully recuperated on corneal biopsy.

■ **IF YOU HAD A SMALL SAMPLE BIOPSY AND WOULD ONLY SEND THE TISSUE TO ONE DIAGNOSTIC LABORATORY, WOULD YOU SEND THE SPECIMEN TO PATHOLOGY OR MICROBIOLOGY AND WHY?**

*Dr. Thompson:* A very small sample biopsy should be sent to pathology. Experimental and clinical studies showed that direct examination of corneal biopsy specimens was superior to cultures in the diagnosis of fungal keratitis. In contrast with cultures, direct examination can confirm a fungal or amebic infection in 1 or 2 days. In addition, panfungal-specific PCR assay performed on DNA extract from paraffin-embedded sections is highly specific and sensitive. It allows rapid screening of ocular specimens for even rare fungal infections.

*Dr. Mabon:* I would first most definitely discuss the case with both the microbiology and pathology personnel. However, I would be most inclined to send the small sample to the microbiology laboratory because the sample could be processed, rinsed, and the resultant volume centrifuged, possibly allowing for a higher diagnostic yield.